



PATIENT

Wallace Doss

SPECIES

Canine

BREED

Yorkshire Terrier

SEX

Male Neutered

AGE

13 years

WEIGHT

19.4lbs

PRESENTING CLINICAL SIGNS

History: Grade II/VI systolic murmur; no clinical signs. Needs dental prophylaxis. BP: 150-160mmHg.

ECHOCARDIOGRAM FINDINGS

2D, m-mode, color flow and Doppler imaging is available.

Left ventricle: The LV diameter is borderline increased with adequate function. LV wall thicknesses are normal.

Left atrium: The left atrium is moderately dilated.

Mitral valve: The mitral valve is diffusely thickened with minimal prolapse into the left atrial lumen. Moderate eccentric mitral regurgitation with a normal velocity.

Aortic valve/Aorta: The aortic valve is normal in morphology and mobility. Normal aortic outflow velocity; laminar flow. No aortic insufficiency.

Right ventricle: Normal right ventricular diameter and morphology indicating no overt evidence of pulmonary arterial hypertension.

Right atrium: Normal RA dimension.

Tricuspid valve: The tricuspid valve appears mildly thickened with moderate tricuspid regurgitation. Velocity consistent with early pulmonary hypertension.

Pulmonic valve/Pulmonary artery: The pulmonic valve is normal in morphology and mobility. No pulmonic insufficiency. Normal RVOT velocity; laminar flow.

Pericardium/other: No pericardial or pleural effusion noted. No obvious cardiac masses.

Heart rhythm: ECG reveals a sinus rhythm with an average HR of 180bpm.

INTERPRETED BY

Maggie Machen
Lamy, DVM
DACVIM (Cardiology)

2-Dimensional Measurements

Ao diam (cm)	1.5
LA diam (cm)	2.4
LA:Ao (Swe)	1.6
IVS thickness (cm)	0.7
LVID diastole (cm)	3.1
PW thickness (cm)	0.7
LVID systole (cm)	1.8
FS (%)	41

Doppler Measurements

PV Vmax (m/s)	0.7
AoV Vmax (m/s)	1.8
MR Vmax (m/s)	6.0
TR Vmax (m/s)	3.0
TR PG (mmHg)	37

IMAGING

PERFORMED BY

Pamela Harrigan,
RDCS

INTERPRETATION OF THE FINDINGS

Chronic degenerative valve disease causing moderate mitral and tricuspid regurgitation. Moderate left atrial enlargement indicates there is relatively low risk for imminent complication, however risk for progression to spontaneous congestive heart failure in the future is elevated. Early pulmonary hypertension is noted which is of unknown significance in an asymptomatic dog. No additional issues are identified.

HOSPITAL NAME

Wignall Animal
Hospital

REFERRING VET

Dr. Colella

Although this patient is borderline for Pimobendan based upon the EPIC criteria, due to concurrent pulmonary hypertension recommend institution at this time as below.

Assessment of progression in the future will help predict long term outcome, however prognosis is guarded at this stage (B2).

INVOICE

22795

DATE

2/24/22



PATIENT

Wallace Doss

SPECIES

Canine

BREED

Yorkshire Terrier

SEX

Male Neutered

AGE

13 years

WEIGHT

19.4lbs

INTERPRETED BY

Maggie Machen
 Lamy, DVM
 DACVIM (Cardiology)

IMAGING PERFORMED BY

Pamela Harrigan,
 RDCS

HOSPITAL NAME

Wignall Animal
 Hospital

REFERRING VET

Dr. Colella

INVOICE

22795

DATE

2/24/22

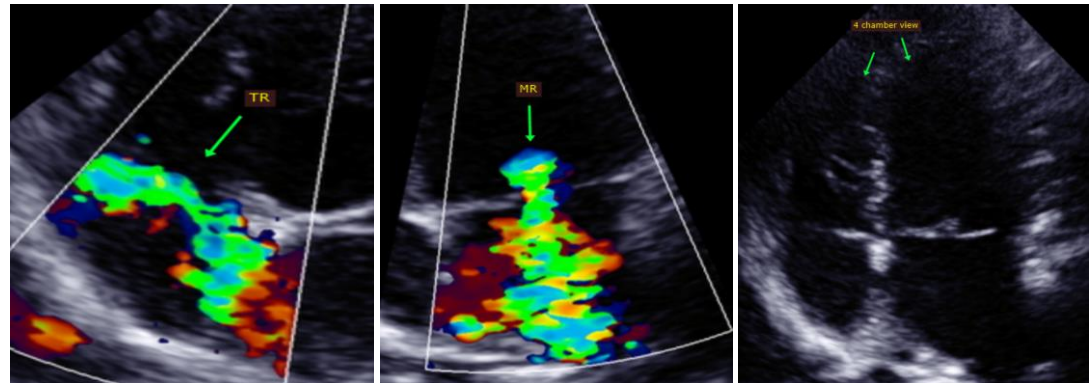
RECOMMENDATIONS

- Institute heart muscle support Pimobendan 0.3mg/kg PO q12h.
- Omega fatty acid supplementation and mild salt restriction may be of some long-term benefit.
- Once on Pimobendan for 3-5 days, anesthetic risk is considered mild if needed. Cardiac protective drug choices (opioid/benzodiazepine premedication, propofol or alfaxalone induction, isoflurane gas) are recommended. Pre-oxygenate for 5-10 minutes prior to induction. Monitor for arrhythmias, hypotension, and hypoxia both intra and post-operatively and intervene as necessary. Mild IV fluid restriction is recommended to avoid fluid overload. Avoid heart rate stimulating drugs such as atropine unless clinically indicated.
- Monitor for development of a cough, labored breathing, exercise intolerance or collapse episodes.

PLAN

- Recommend conservative monitoring with a recheck echocardiogram in 6 months, sooner if any development of clinical signs.

IMAGES



The information and recommendations provided are based on the images presented by the referring veterinarian. No evaluation can be communicated regarding pathology that was not visible in the image/video clips provided.

Thank you for this referral. This report was generated using transcription software, and minor dictation errors may be present. If the clinical or image interpretation does not parallel your findings or if I can be of any further assistance, please contact me.

Maggie Machen Lamy, DVM
 Diplomate of the American College of Veterinary Internal Medicine (Cardiology)
 info@sonopath.com